



# Treatment of focal articular cartilage lesions of the knee with autogenous osteochondral grafts

*Aghayev E, Orljanski W, Millenkivics H, Zazirnyj I\*, Schabus R*

**Department of Sport Traumaology (Head Prof. Dr. R. Schabus)  
Vienna Privat Klinik  
Vienna, Austria**

**(\* Orthopaedic department  
State Hospital N-12  
Kiev, Ukraine**

**Abstract** A retrospective study of 14 patients with 14 knees who underwent osteochondral autografts for focal full thickness articular cartilage defects of the knee with 2 year follow-up showed 90% good or excellent clinical results. There was no correlation of the clinical results with the underlying diagnoses, including osteonecrosis, osteochondritis dessicans and traumatic cartilage defect. The improvement in symptoms appeared time-dependent, ranging from 6 to 16 weeks, suggesting that postoperative protection of the graft is warranted. There was no radiographic progression of degenerative changes of the knee on the medium-term follow-up. Therefore, an autogenous osteochondral graft is considered a good method in the treatment of knees with moderately sized articular cartilage defects.

**Keywords** Osteochondral graft • Cartilage lesion • Knee

## Introduction

A chondral / osteochondral defect involving the articular surface of a joint is still a therapeutic problem. A full-thickness articular cartilage defect of the knee frequently results in fibrous tissue formation and degenerative changes and a defect larger than 9 mm often leads to degenerative arthritis of the knee [2]. Many surgical techniques including microfracture, periosteal and perichondral grafts, chondrocyte transplantation, chondrogenesis-stimulating factors, gene therapy, osteochondral grafts, etc. have been studied in an attempt to restore the damaged articular cartilage [1, 4, 5, 7, 8, 9]. However, there is no consensus of opinion on the best method to repair full-thickness articular cartilage defects of the knee.



Autogenous osteochondral graft has gained in clinical popularity because of its technical feasibility and cost effectiveness. However, only a few series have been reported in the literature in any of them case reports [1, 3, 4, 8]. The purpose of this study was to review the results of 14 patients with 14 knees undergoing osteochondral autograft to repair focal full-thickness articular cartilage defects of the knee with a minimum of 2 years follow-up.

## Patients and methods

Fourteen patients with 14 knees undergoing autogenous osteochondral graft for focal articular cartilage defects of the knee between January 1997 to June 2000 were included in this study. There were 8 men and 6 women with an average age of 33 (range 20-55) years old. The average age was 42 years for patients with osteonecrosis, 26 years for patients with osteochondritis dessicans, and 35 years for patients with traumatic defects. Eight times the right knee was affected and the left knee in the other 6 cases. The average duration of Symptoms was 13.6 (range 4-40) months, and the average follow-up time was 24 (range 22-27) months.

The diagnoses included 6 knees with osteonecrosis, 5 with osteochondritis dessicans, and 3 with traumatic cartilage defect. The locations of the lesion included the lateral femoral condyle in 9 knees, medial femoral condyle in 4 knees. The average size of the lesion was 330 (range 130-490) mm<sup>2</sup> for the lateral femoral condyle and 207 (range 120-375) mm<sup>2</sup> for the medial femoral condyle. The types of injury included 3 motor vehicle accidents, 1 falling accidents, 3 sports-related injuries (2 basketball and 1 badminton), 1 work-related, 1 steroid-induced (systemic lupus erythematosus), and 5 unknown. The prior surgeries included 5 knees with abrasion chondroplasties and removal of loose fragments, 4 meniscectomies, 1 meniscal repair, and 1 anterior cruciate ligament reconstruction.

All 14 procedures were performed arthroscopically. The Arthrex osteochondral transfer instruments (Arthrex,



Naples, Fla.) were utilized in all cases. The damaged and detached articular cartilage was debrided to the bleeding subchondral bone first. The number and length of osteochondral plugs were determined according to the size and depth of the lesion. The predetermined bone plugs were removed from the lesion (recipient site). Then 1.0 mm oversized osteochondral plugs of the same length were harvested from the articular cartilage either around the intercondylar notch or the sulcus terminalis of the lateral femoral trochlea, and were transplanted into the recipient site. The osteochondral plug was secured at the recipient site by the press-fit technique. The surfaces of the osteochondral cores were made flush with the surrounding articular cartilage. Special attention was paid to avoid fracture or breakage of the osteochondral plugs during the course of transplantation. The number of osteochondral plugs used ranged from 1 to 5. An attempt was made to place the osteochondral plugs within 1.0 mm proximity to each other when more than two plugs were used. The bone plugs from the recipient site were implanted into the defects of the donor site. The wounds were closed in a routine manner.

Prophylactic antibiotic (spizef) was given before and every 12 h after surgery for 72 h. Postoperatively, patients received continuous passive motion (CPM) exercises, but remain non-weight-bearing for 12 weeks. Quadriceps and hamstring strengthening exercises were encouraged.

The evaluations were based on functional assessments, which included pain, giving way, locking, recurrent effusion, knee scores, functional scores, and Lysholm scores. Radiographs of the knee were examined for joint congruence, joint space narrowing and degenerative changes.

## Results

All patients were operated on because of knee pain ranging from mild to severe preoperatively. Postoperatively, 11 of 14 knee (78.5%) had no pain and 3 knees (21.5%) showed mild pain ( $p=0.001$ ). The duration to pain relief of the knee ranged from 6 to 16 weeks after surgery. A history of the knee giving way was present in 11 of 14 knees (78.5%) preoperatively and in no one postoperatively.

**Table 1** Pre- and postoperative functional assessment of the knee after osteochondral graft (ROM range of motion)

	Preoperative	Postoperative	<i>p</i> value *
No. of cases	14	14	
Knee pain			0.001
None	0	12 (85.7%)	
Mild	5 (35.7%)	2 (14.3%)	
Moderate	8 (57.2%)		
Severe	1 (7.1%)		
Giving way			0.002
None	4 (28.6%)	14 (100%)	
Mild	5 (35.7%)		
Moderate	5 (35.7%)		
Locking			0.001
None	1 (7.1%)	14 (100%)	
Mild	9 (64.3%)		
Moderate	4 (28.6%)		
Effusion			0.002
None	3 (21.5%)	13 (92.9%)	
Mild	5 (35.7%)	1 (7.1%)	
Moderate	5 (35.7%)		
Severe	1 (7.1%)		
ROM			0.005
Mean±SD	122.8°±8.8°	134.4±7.9	
Range	105°. 135°	115°. 145°	
Lysholm score			0.001
Mean±SD	67.9±12.4	90.4±10.1	
Range	48, 86	67, 100	

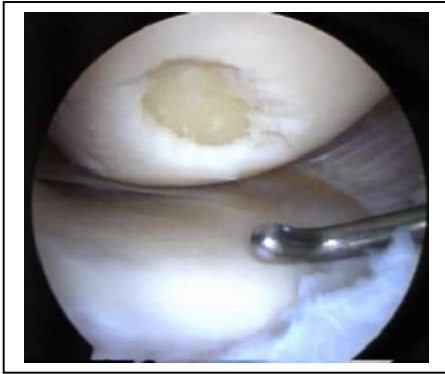\*Wilcoxon Signed Rank test

Knee locking was noticed in 13 knees (92.8%) preoperatively and no one postoperatively ( $p=0.001$ ). Recurrent knee effusion was seen in 11 of 14 knees (78.5%) preoperatively and in only 1 knee (7.1%) postoperatively ( $p=0.002$ ). The average range of knee motion was 122.8°±8.8° preoperatively vs 134.4°±7.9° postoperatively ( $p=0.005$ ). The average Lysholm scores were 67.9±12.4° preoperatively vs 90.4±10.1° postoperatively ( $p=0.001$ ). The average knee score was 94±12 and the average functional score 88±15 at follow-up. The results of functional assessments of the knee are summarized in Table 1. The overall results were excellent in 7 (43.75%), good in 6 (37.50%), fair in 2 (12.50%), and poor in 1 (6.25%).

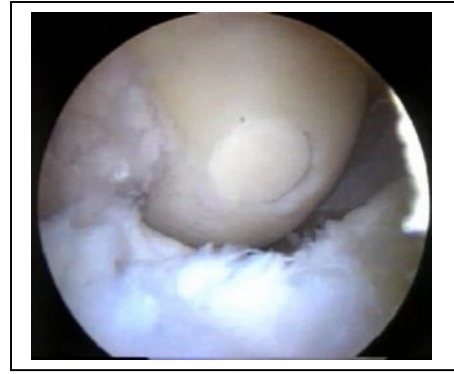The preoperative radiographs of the knee showed mild degenerative changes in 6 knees with involvement of

the medial compartment in 4, lateral compartment in 1, and patellofemoral joint in 1. Postoperatively, the incidence of degenerative changes of the knees by radiographic examination was noticed in 7 knees with 4 in the medial compartment, 2 in the lateral compartment, and 1 at the patellofemoral joint.

The postoperative values of functional assessments among the three categories of diagnosis (osteonecrosis, osteochondritis desiccans, and traumatic cartilage defect) were compared statistically using Kruskal-Wallis test with statistical significance set at  $p < 0.05$ . The results showed that there was no statistically significant difference in the functional assessments including pain, swelling, giving way, and locking of the knee and the Lysholm scores among these three categories ( $p > 0.05$ ).



**Fig. 1**



**Fig. 2**

**Fig. 1:** Arthroscopic appearance of an osteochondral a medium-size defect of the medial femoral condyle due to trauma.


**Fig. 2:** Arthroscopic appearance of same osteochondral defect of the medial femoral condyle after autogenous graft implantation.

## Discussion

This study showed good or excellent results for 90% of the knees after an osteochondral autograft for a focal articular cartilage lesion of the knee. Marcacci et al. reported that 12 of 13 knees with an articular cartilage defect greater than 1.5 cm<sup>2</sup> which were treated by osteochondral graft showed satisfactory results, and the patients were able to resume their pre-injury level of activities. There was 1 case with a poor result [7]. Solheim reported satisfactory results for 33 patients undergoing osteochondral grafts for knees with an average cartilage lesion of 2.8 cm<sup>2</sup> and recommended such an Operation for knees with a moderately sized osteochondral lesion (1-5 cm<sup>2</sup>) [9]. Hangody et al. reported 91% good or excellent results in 57 of 227 patients undergoing an osteochondral graft of the knee with more than 3 years' follow-up [4]. The results of our study were comparable with other reported series [1, 4, 9].

The average duration to pain relief of the knee ranged from 6 to 16 weeks after surgery. The improvement of Symptoms appeared to be time-dependent. Lane et al. reported that the osteochondral graft remained viable, functionally and structurally intact for 12 months in a rabbit model. The subchondral bone underwent replacement in less than 6 weeks [6]. Dew and Martin showed that osteochondral grafts incorporated radiographically in 12 weeks in an experiment involving the talus of dogs [3]. Wang et al. studied osteochondral gratis in pigs and found that the subchondral bone healed and remodeled in 4 weeks, which provided better stability and nutrients for the graft; the cartilage healed to the adjacent cartilage by direct bonding in 12 weeks or longer [10]. Our results were supported by the studies by Lane et al. and Wang et al. that knee pain improved when the graft became stable, with remolded subchondral bone healing in 4-6 weeks after the osteochondral graft and eventual cartilage healing in approximately 12 weeks or longer. The grafts remained viable and were structurally intact up to 32 months based on a second-look arthroscopic examination.

This study showed that there was no statistical correlation of the results after an osteochondral autograft with the underlying diagnoses, including osteochondritis desiccans, osteonecrosis, and traumatic defect of the articular cartilage as long as the size of the lesion was smaller than 500 mm<sup>2</sup>. There was no statistical correlation of the results with the size of the lesion smaller than 500 mm<sup>2</sup> as long as there was a sufficient number of osteochondral plugs implanted in dose proximity and there was good graft stability. However, larger lesions were associated with increasing fibrous tissue formation and fissuring between the grafts and the surrounding tissues according to a second-look arthroscopic evaluation despite a good clinical outcome. An articular cartilage lesion of the knee larger than 500 mm<sup>2</sup> is at risk for a poor result even after an osteochondral autograft. The findings of this study



were in agreement with those of Solheim [9] that osteochondral mosaicplasty may be considered in cartilage lesions of moderate size (1-5 cm<sup>2</sup>) on the femoral condyle.

The postoperative incidence of degenerative changes of the knee was similar to the preoperative Status. All knees except 1 with radiographic evidence of degenerative changes preoperatively showed no progression of degenerative changes of the knee postoperatively. It appeared that osteochondral autografts did prevent or delay the development of degenerative changes of the knee in the medium-term follow-up.

In conclusion, the osteochondral autograft achieved a high rate of good or excellent clinical results in knees with focal full-thickness articular cartilage defects. There was no correlation of the clinical results with the underlying diagnoses including osteochondritis dissecans, osteonecrosis, and traumatic defect of the articular cartilage. There was no direct correlation of the clinical results with the sizes of the lesions smaller than 500 mm<sup>2</sup>, but lesions larger than 500 mm<sup>2</sup> tended to result in increasing fibrous tissue formation and fissuring between the grafts and the surrounding tissues and poor results. The improvement of knee pain was time-dependent, ranging from 6 to 16 weeks, and postoperative protection of the graft was warranted. It appears that an osteochondral graft has the potential to prevent or delay the development of degenerative changes of the knee in the medium-term follow-up. Therefore, an autogenous osteochondral graft is considered a good method of treatment in knees with a moderately sized full-thickness articular cartilage defect.

## References

1. Beriet GC, Mascia A, Miniaci A (1999) Treatment of unstable osteochondritis dissecans lesions of the knee using autogenous osteochondral grafts (mosaicplasty). *Arthroscopy* 15: 312-316
2. Buckwalter JA, Mankin HJ (1998) Articular cartilage repair and transplantation. *Arthritis Rheum* 41: 1331-1342
3. Dew TL, Martin RA (1992) Functional, radiographic, and histologic assessment of healing of autogenous osteochondral grafts and full thickness cartilage defects in the talus of dogs. *Am J Vet Res* 53: 2141-2152
4. Hangody L, Kish G, Karpati Z, et al (1998) Mosaicplasty for the treatment of articular cartilage defects: application in clinical practice. *Orthopedics* 21: 751-756
5. Kish G, Modis L, Hangody L (1999) Osteochondral mosaicplasty for the treatment of focal chondral and osteochondral lesions of the knee and talus in the athlete. *Rationale, indications, techniques, and results. Clin Sports Med* 18: 45-66
6. Lane JM, Brighton CT, Ottens HR, Lipton M (1997) Joint resurfacing in the rabbit using an autologous osteochondral graft. A biochemical and metabolic study of cartilage viability. *J Bone Joint Surg Am* 57: 218-222
7. Marcacci M, Kon E, Zaffagnini S, Visani A (1999) Use of autologous grafts for reconstruction of osteochondral defects of the knee. *Orthopedics* 22: 595-600
8. Matsusue Y, Yamamuro T, Hama H (1993) Arthroscopic multiple osteochondral transplantation to the chondral defect in the knee associated with anterior cruciate disruption. *J Arthritis Rel Surg* 9: 318-321
9. Solheim E (1999) Mosaicplasty in articular cartilage injuries of the knee. *Tidsskr Nor Laegeforen* 119: 4022-4025
10. Wang CJ, Chen HS, Cheng SM, et al (2000) Cartilage repair by osteochondral graft in the knees of pigs – a histological study. *J Musculoskeletal Res* 4: 135-143

*Adress reprint requests to:*

Dr. E. Aghayev  
Department of Sport Traumatology  
Vienna Privat Clinic  
Pelikangasse 15  
A- 1090 Vienna  
Austria  
Tel.: +43 1 40180-7790  
Fax: +43 1 40180-780  
Email: [emin94@yahoo.com](mailto:emin94@yahoo.com)